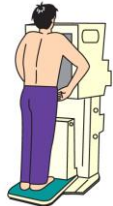

Interpretation of Chest X-ray Findings

- A** You have no abnormal chest X-ray findings.
B You have abnormal chest X-ray findings as described in your report, but you do not need an interview with medical staff, further tests or treatment to attend or work in school.
C You have abnormal chest X-ray findings as described in your report, and you need an interview with medical staff, further tests or treatment to attend or work in school.

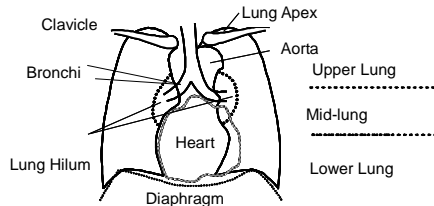
If your result is "A" or "B", you have no problem attending or working in school. You will be required to undergo the next periodic health examination and if you have symptoms such as persistent cough and low fever, please seek medical advice as soon as possible.

If you are under the care of a physician, please report the test results to your physician.



What Does a Chest X-ray Reveal?

A chest X-ray is performed to detect active pulmonary tuberculosis. Other diseases of the lungs and heart might also be found by the chest X-ray.



* Pleura: The pleura is the serous membrane enveloping the lungs and lining the walls of the pulmonary cavities.

* Mediastinum: The mediastinum is the median partition of the thoracic cavity, containing all of the thoracic viscera and structures except the lungs.

Active and Inactive Pulmonary Tuberculosis, Primary Complex

肺結核 (活動性), 肺結核 (不活動性), 初期変化群

The symptoms of tuberculosis infection (cough, sputum, low fever, night sweats, fatigue) typically develop slowly and such individuals are likely to infect others. The cases of inactive tuberculosis must be regularly monitored for signs of recurrence. The cases of active tuberculosis require immediate treatment and preventive care.

Nontuberculous mycobacterial disease 非結核性抗酸菌症

Nontuberculous mycobacteria (NTM) are mycobacteria which do not cause tuberculosis or Hansen's disease. Infection occurs rarely through contact with soil, dust or water. NTM infections are usually not contagious, but in advanced cases, treatment is required.

Thoracoplasty, Postoperative Changes 胸郭形成, 術後変化

Reveals the postoperative changes in the pleura and the lungs.

Pleural Thickening, Adhesion 胸膜肥厚・癒着

Condition mainly brought on by past inflammation, surgery or structural changes in the subpleural lung tissue. It requires follow-up care, but conditions that accompany respiratory symptoms require treatment. Divers should consult a physician specializing in the respiratory system before diving.

Pneumothorax 気胸

Condition in which air leaks into the pleural space, creating pressure against the lung that causes the lung to collapse. Treatment is required.

Pleural Effusion 胸水

Condition that results from the accumulation of fluid between the pleura lining the lung and the wall of the chest cavity. Possible underlying causes include pleural and lung disease, cardiovascular disease and intra-abdominal disease.

Thoracic Deformity, Dysplasia / Azygos Lobe 胸郭変形, 形成異常・奇静脈葉等

Indicative of abnormalities in the formation of a bodily structure, such as the lungs, blood vessels and the ribs.

Diaphragm Elevation 横隔膜挙上

An abnormally high position of the diaphragm which may be caused by obesity, pleural thickening and digestive system disease.

Hernia ヘルニア

A hernia is an abnormal weakness or hole in the muscular wall which allows abdominal contents to protrude into the chest cavity through the esophageal opening in the diaphragm. Any serious chest pain and nausea should receive prompt medical attention.

Post-inflammatory Changes 炎症後変化

Destruction or deterioration of normal lung structure and function caused by the inflammation of the lungs and the bronchus. If the underlying cause is treated, the patient should be put on observation.

Calcification 石灰化

Calcification is a process characterized by the formation of calcium deposits, caused by factors such as aging and inflammation.

Increased Lung Markings 肺紋理増強

Condition in which the shadow of the pulmonary artery and vein is expanded. If a diagnosis has not been made, its cause must be determined.

Lung Cyst 肺嚢胞

Condition in which there is an abnormal sac (bullae, blebs) in the lung, which may rupture spontaneously or by sudden pressure changes. Divers should consult a physician specializing in the respiratory system before diving.

Lung Cavity 空洞

Lung cavity is formed by necrosis of the lung tissue, caused by congenital diseases or inflammation. Activity of the causative disease must be determined.

Atelectasis 無気肺

Loss of air in the alveoli caused by a blockage of the bronchus or a space-occupying intrathoracic process. The presence of an underlying disease must be determined.

Pulmonary Edema 肺水腫

An abnormal build up of fluid in the lungs, primarily caused by heart failure or renal failure. Treatment is required.

Bronchodilation 気管支拡張

An expansion of the air passages through the bronchi of the lungs, primarily caused by congenital abnormalities and inflammation. Treatment is required for repeated infection or hemorrhage.

Enlarged Lymph Node リンパ節腫大

Condition in which the lymph node(s) is swollen. Underlying disease and its activity must be determined.

Nodular Shadow, Neoplastic Shadow, Emphysematous Changes, Interstitial Shadow, Ground Glass Opacity, Infiltrative Shadow / Patchy Shadow, Linear Shadow / Band-like Shadow, Reticular Shadow, Granular Shadow

結節性陰影, 腫瘍性陰影, 気腫性変化, 間質性陰影, スリガラス状陰影, 浸潤影・斑状影, 線状影・索状影, 網状影, 粒状影

The above are all shadows which may indicate a variety of lung diseases. Causes and activities should be considered.

Angiectopia 血管走行等の異常

An abnormal position or course of a vessel, which may be caused by congenital disease or aging.

Aortic Calcification 大動脈石灰化

Condition in which large calcium deposits form on the aorta, which is an indication of atherosclerosis.

Protrusion of the Left Second, Third, Fourth and Right Second Aortic Arches

左第二弓突出, 左第三弓突出, 左第四弓突出, 右第二弓突出

This is indicative that part of the heart is enlarged due to a heart disease. Further tests are recommended. There may be findings related to obesity, thoracic deformity or poor inspiration, even if no heart abnormalities are present.

Post-cardiac Operative Changes 心臓術後変化

Reveals the presence of a cardiac surgical scar (including pacemaker implantation).

Dextrocardia 右胸心

Condition in which the heart is displaced to the right side of the chest. Treatment is not necessary if there is no associated malformation.

Spinal Curvature 脊柱弯曲

An abnormal change in the position of the backbone or spine, which is often associated with a twist in the spine itself.

Abnormal Bone Shadows 骨陰影の異常

Findings in the bones indicative of bone fracture or an abnormality in the formation of bones.

Postoperative Changes in the Bone 骨術後変化

Postoperative conditions may show the presence of medical apparatus such as reinforcement metals.

Medical Apparatus, etc. 医療器具等

The presence of medical apparatus such as needles and magnets.

CTR(cardiothoracic ratio) 心胸郭比

The cardiothoracic ratio is obtained by dividing the transverse cardiac diameter by the transverse thoracic diameter. The ratio is an indicator of cardiac enlargement.

